

Mini Screw Implants As A Source Of Intra Oral Anchorage For En-Masse Intrusion Of Maxillary Anterior Teeth- A Case Report

Bhavna Virang *, P.G.Makhija **, Anup Belludi ***, Parag Virang ****, ShubhamAgrawal*, Amit Bhardwaj***.

Abstract:

Overbite correction often offers a challenge to the clinician during orthodontic treatment. Bite opening with conventional mechanics in high angle cases which require intrusion of anteriors cause reciprocal forces in the posteriors which is undesired. Absolute or true En-masse Intrusion mechanics using mini implants are ideal for such cases. Mini implants deliver light continuous forces of optimal magnitudes and they are efficient and stable source of anchorage for en masse intrusion of the maxillary anterior teeth. Here we have presented a case of en-masse intrusion of maxillary anteriors by implants. The amount of intrusion achieved for six maxillary anterior teeth was statistically and clinically significant without significant torque changes.

Key words: mini screws, absolute intrusion, anchorage.

Introduction

Intrusion is a desirable orthodontic tooth movement limited principally by inadequate dental anchorage. When arch wire is designed to develop an intrusive force anteriorly it simultaneously generates a reactive extrusive force in the posteriors. These undesirable extrusive components on posterior teeth are opposed mainly by occlusal forces. In high angle cases, the occlusal forces may be inadequate and the reactive extrusive force can lead to extrusion of molars and downward and backward rotation of the mandible resulting in unfavourable facial profile changes.¹

In many clinical situations the canines are also in deep bite and require intrusion. There are limited options for En-masse intrusion with conventional mechanics and may lead to undesired reactionary changes in the posteriors.^{2,3,4} A method of overcoming these undesirable changes is by the use of orthodontic mini implants.⁵ A case report in which mini screw implants are used for en masse intrusion is presented here.

Case reports

A 19 year old male patient reported for treatment in the Department of Orthodontics & Dentofacial Orthopaedics, Modern Dental College & Research Center.

Patient had molar class I canines class II relation bilaterally with increased overjet and overbite. Case was started with 022 MBT prescription and upper first premolar extraction. Camouflage treatment to correct canines to class I relation and correct overjet and overbite were taken as treatment objectives.

The upper arch was divided into two posterior stabilizing segments with 0.019 x 0.025" Stainless steel wire and one anterior intrusive segment with a 0.021x 0.025" stainless steel wire. In the anterior segment two loops were bent in the wire between lateral incisor and canine. Implants were immediately loaded with 90 gms of intrusive force (45 gms each side) with the help of e-chain (fig. 1). 20 gms of

* Senior Lecturer

** Professor and Head

***Professor

**** Clinical Practitioner, Dept of Oral Surgery

Department of Orthodontics, Modern Dental College & Research Centre, Indore.

Class I force was delivered per side to avoid flaring of anteriors.

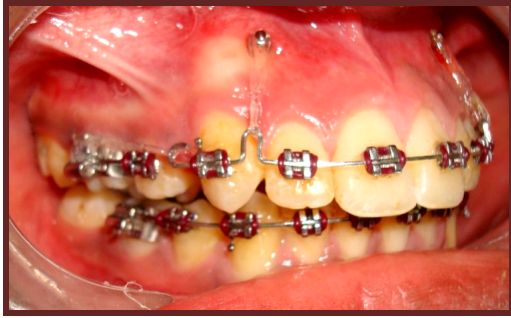

Figure -1 : Intrusive segment with implants

Bilateral Mini implants (1.3mm in diameter and 8 mm in length DENTOS India) were placed between upper lateral incisors and canines . The implants were placed after using acrylic bar guide and IOPA x-rays to check for precise locations. After placing implants IOPAR were taken to check the correct position between the roots. The following landmarks were used for analysis (fig. 2).

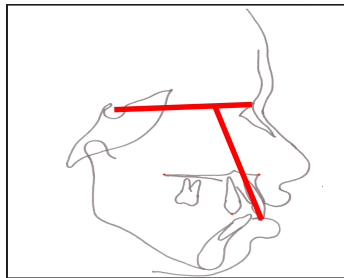


Figure -2 : Cephalometric landmarks taken

S: (Sella Turcica) A constructed point representing the center of the pituitary fossa.

N: (Nasion) The most anterior point of the nasofrontal suture

Ia: (Incisor apex) The root apex of the most prominent incisor

Io: (Incisor occlusal) The incisal point on the most prominent incisor

To check the maxillary central incisor vertical movement(intrusion). Io – SN(mm) ie: Linear distance between the incisal edge of the maxillary central incisor and SN plane was measured .

Lateral cephalogram was taken at the beginning of intrusion and after 6 months of intrusion to compare the amount of intrusion.

Results

Rate of intrusion of incisors was calculated as follows:

$$\text{Rate of intrusion of incisors} = \frac{\text{Amount of intrusion}}{\text{Treatment time (months)}}$$

$$\frac{2.58}{6.0} = .43/\text{month}$$

DISCUSSION

Mini implants have proven to be a useful addition to the orthodontist's armamentarium for control of anchorage, and has gained enormous credibility in the clinical management of various orthodontic tooth movements. Here we have used mini implants as a source of anchorage during enmasse intrusion in first premolar extraction cases although this mechanics can be deployed in non-extraction cases too provided there is enough space. A very light force of 15-20 gms per tooth is recommended for intrusion.^{6,7,8,9} It has been documented that the use of heavier force will not increase the rate of intrusion, instead it may lead to root resorption.¹⁰

During en masse intrusion of all the six teeth, it was observed that the canines were intruded less than the centrals and laterals. The reason for this may be assumed that the canine roots are long and having more surface area hence may need more force compared to the incisors secondly amount of intrusion may depend upon inclination of tooth, approximation of root to cortical plate and as the canine roots usually are torque labially.

For any root form, there is a point where application of a single force would cause pure translation of tooth without either rotation or tipping. This point is called centre of resistance.¹² True intrusion takes place when forces are directed through the center of resistance.¹³ If the intrusive force is applied anterior to the centre of resistance of a segment, it results in flaring of the teeth. To prevent this, in the present

case, about 20gms of class I force was applied with a pre stretched elastic chain from the molar hook to distal of canine. The forces were just enough to prevent flaring.

Evaluation of the lateral cephalograms was done at the end of six months and it was observed that rate of intrusion of incisors was found out to be .43 mm / month (fig 3,4).

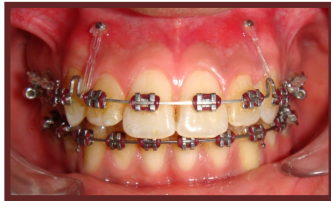
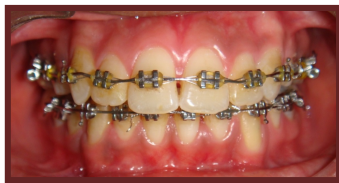
Figure -3: Pre- intrusion



-4: Post- intrusion

Figure

Conclusion

The advent of mini implant has reduced anchorage concern to a great extent. This case has elucidated the clinical effectiveness of mini implants for the purpose of en masse intrusion of all the six maxillary anterior teeth in a single step instead of the traditional; two step intrusion of canine and incisors. This approach not only eases the biomechanics involved and also eliminates any reciprocal reactionary forces in the posteriors.

References

1. Southard T E, Buckley M T, Spivey J D, Krizen K E, Casco J S. Intrusion anchorage potential of teeth versus rigid endosseous implants; A clinical and radiographic evaluation . Am J Orthod Dentofacial Orthop 1995;107: 115-20 .
2. T K Kim, J T Kim, J Mah, W S Yang, and S. H. Baek . First or second premolar extraction effects on facial vertical

dimension. *Angle Orthodontist* 2005; 75: 177–182.

3. H B Ong and M G Woods .An occlusal and cephalometric analysis of maxillary first and second premolar extraction effects . *Angle Orthodontics* 2001 ; 71: 90–102.

4. I Kocadereli .The effect of first premolar extraction on vertical dimension . *American Journal of Orthodontics* 1999 vol; 116: 41–45.

5. Ohnishi H, Yagi T, Yasuda Y, Takada K. A mini-implant for orthodontic anchorage in deep overbite case. *Angle Orthodontics* 2005; 75 :444-452.

6. Burstone CJ. Deep overbite correction by intrusion. *AM J orthod* 1977; 72: 1-22.

7. Handam AM, Rock WP .The effects of archwire forces on incisor intrusion. *British Journal of orthodontics* 1995; 22:155-160.

8. Nanda R. Correction of deep overbite in adults . *Dental Clinics of North America* 1997; 41 (4) :67- 81.

9. Ponitz PV .Increasing intrusion of anterior teeth. *Am J orthod Dentofacial Orthop* 1988; 514-515.

10. Smith RJ, Burstone CJ. Mechanics of tooth movement. *Am J Orthod* 1984; 85: 294-307.

Corresponding Author:

Dr. Bhavna Virang MDS

Senior Lecturer

Department of Orthodontics & Dentofacial Orthopedics

Modern Dental College and research centre, Indore (M.P.)

Email:- bhavnamds@gmail.com