

RHINOMAXILLARY MUCORMYCOSIS: A CASE REPORT

AratiChaudhary*, P. V. Wanjari**, Noopur Shrivastava***,

Abstract

Mucormycosis is a rare opportunistic fungal infection caused by saprobic organism belonging to the order mucorales. The rhinocerebral form is the most commonly reported form of mucormycosis that typically starts in the maxillary antrum, particularly in poorly controlled diabetics. Early recognition of mucormycosis is necessary to avoid cerebral extension which can lead to high morbidity and mortality. A case of mucormycosis presenting as ulcerated lesion of the palate is discussed in this article.

Key words: Mucormycosis, Phycomycosis, Rhinomaxillary, Palatal perforation, Diabetes

Introduction:

Mucormycosis also called as zygomycosis or Phycomycosis was first described by Paultauf in 1885¹. It is the rapidly progressing lethal form of fungal infection in humans, which usually begins in nose and paranasal sinuses². It is an opportunistic fungal infection that is caused by normal saprobic organisms of the class zygomycetes including such genera as Mucor, Absidia, Rhizopus and Cunninghamella¹.

Fungal pathogens are subdivided into those that remain superficial (restricted to epithelial surface) and those that invade deep organs and tissues (deep fungi). Some species are considered opportunistic (infecting only immunocompromised host) and others truly pathogenic (capable of infecting normal persons)³. The fungus causing mucormycosis is opportunistic fungi and invade the human body by either inhalation or ingestion. Then it invades the arteries, forms thrombi within the blood vessels that reduce blood supply and cause

necrosis of hard and soft tissues. This thrombus itself acts as a medium for the growth of the fungus².

The rhinocerebral form is the most commonly reported form of mucormycosis, which is characterized by progressive fungal invasion of hard palate, paranasal sinuses, orbits and brain. Successful management of this fulminant infection requires early recognition of the disease, aggressive medical and surgical interventions to prevent the high morbidity and mortality associated with the disease process⁴.

Case Report:

A 48 years old male patient reported to Dept. of Oral Medicine and Radiology, Modern Dental College and Research Center, Indore, with a painful ulcer in upper front tooth region on the left side of the jaw since 2 yrs. History reveals that the ulcer was gradually increasing in size posteriorly and was associated with nasal regurgitation, frequent headaches and numbness. His

*Professor

**Professor and Head,

***P.G. Student, Department of Oral Medicine and Radiology,

Modern Dental College and Research Center, airport road, Gandhi nagar, Indore.

medical history was significant for uncontrolled diabetes since 5 yrs and controlled COPD since 2 months. On general physical examination the patient was moderately built and had paresthesia on the left side of the face over the region of zygoma and upper lip. The submandibular lymphadenopathy on the left side was nontender.

Intraorally, a single large ulcerated lesion exposing the underlying necrotic alveolus was noticed that was devoid of mucosa and was foul smelling (fig.1). The ulcer extended from 21 to 24 region posteriorly and measured 4x5 cm in size. Based upon the history and clinical examination the case was provisionally diagnosed as nonsuppurative osteomyelitis of the left maxillary alveolus with the differential diagnosis of mucormycosis, wegener's granulomatosis, malignant ulcer and tubercular ulcer.

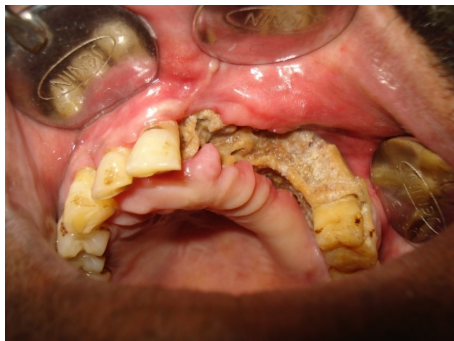

Fig 1: ulcerated lesion on the left maxillary sinus

Lab findings were significant for raised ESR of 78 mm/hr, a fasting blood glucose level of 104mgm% and post prandial glucose level of 213mgm%. The patient was negative for HIV, tuberculosis and HBsAg.

The paranasal sinus view showed haziness of right and left maxillary sinus and frontal sinus on left side. Orthopantomograph showed empty sockets with 21,22,23 and 24 and an ill defined radiolucency with respect to maxillary alveolar bone, involving floor of maxillary sinus and floor of nasal fossa. A computed tomographic scan of maxillofacial region revealed destruction and moth eaten appearance of palate and nasal fossa (fig II), with erosions seen along antero-inferior, posterolateral as well as posteromedial walls of left maxillary sinus.

An incisional biopsy of the hard palate region was performed and histopathological investigations were conducted. H & E stained slides showed thin walled, aseptate hyphae of nonuniform diameter. Periodic acid Schiff (PAS) stained slides showed broad aseptate fungal profiles, 10-15 um wide, thin walled hyphae showing frequent bulbous dilatations confirming the morphology of phycomycetes group of fungi (fig III). Gomori's methenamine silver (GMS) stain for fungi showed fungal hyphae of mucormycosis, positive for GMS.

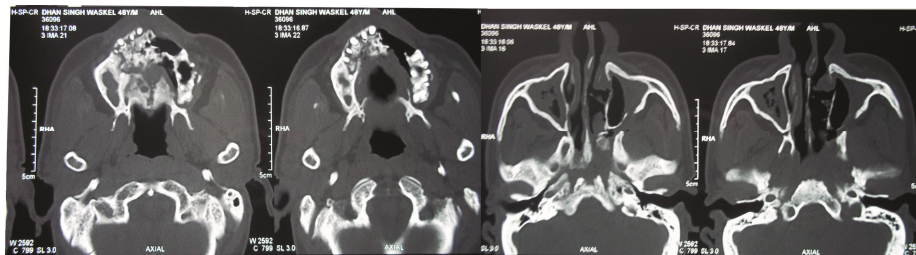


Fig 2: CT scan showing destruction of palate and nasal fossa

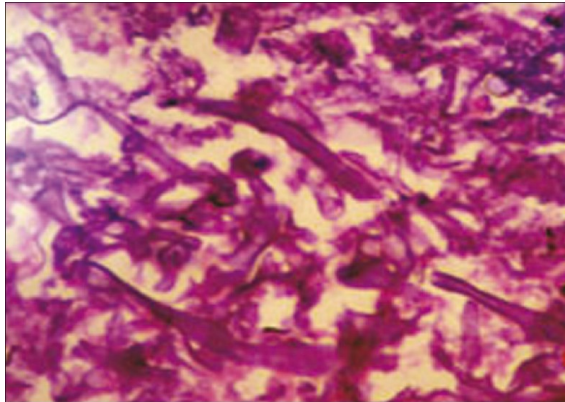


Fig 3: histopathological picture of the lesion

The patient was subjected to aggressive surgical debridement, systemic amphotericin B in the dose of 1mg/kg/day over 4-6 hr. IV for 3 weeks. After 3 weeks the condition improved and oral amphotericin B was initiated.

Discussion:

Mucormycosis or Zygomycosis presents as a spectrum of disease, depending on the portal of entry and predisposing risk factors of the patient. The three primary mucor invasion are the nasal sinuses, lungs and gastrointestinal tract, depending on whether the spores are inhaled or ingested. In diabetics the fungus may spread from nasal sinuses to the orbit and brain, giving rise to rhinocerebral mucormycosis, a subdivision of which is the rhinomaxillary form.³

Mucorales attack people with compromised immune system. The predisposing factors are Diabetes (especially when associated with ketoacidosis or uncontrolled diabetes), Hematological malignancies (leukemia, lymphoma), Solid organ or bone marrow transplant, Corticosteroid use, Desferroxamine therapy (Rhizopus species prefers an iron rich

environment), Severe and prolonged neutropenia, Deficient T-cell immunity, Immaturity and low birth weight.³

Reduced ability of the serum to bind iron at low pH may be the basic defect in body's defense system. Fungal hyphae produce a substance called rhizoferrin (siderophores) which bind iron avidly. This iron-rhizoferrin complex is then taken up by the fungus and becomes available for vital intracellular processes¹. Human infection is said to be caused by asexual spore formation. The tiny spore then become airborne and land on the oral and nasal mucosa of humans. If the immunity of the person is reduced causing failure of phagocytic response against this antigen, then the germination of the fungi ensue and fungal hyphae will develop. Once the hyphae enter the blood stream through invasion into the arteries, they form thrombi within the blood vessels that reduce vascularity to the tissues and cause necrosis².

Peripheral vascular disease (due to microangiopathy and atherosclerosis) in diabetic patients also cause local tissue ischemia and increased susceptibility to infections. Therefore thrombosis of internal maxillary artery and ascending palatine artery as well as chronic uncontrolled diabetes in this patient had resulted in necrosis of maxilla².

Patients with rhinocerebral mucormycosis usually present in the early stages of disease with malaise, headache, facial pain, swelling, low grade fever, nasal discharge, anesthesia and necrotic turbinates^{4,2}. Extension can lead to orbital involvement with impairment of functions of cranial nerves III, IV and VI resulting in proptosis, ptosis, papillary dilatation, orbital

*Professor

**Professor and Head,

***P.G. Student, Department of Oral Medicine and Radiology,

Modern Dental College and Research Center, airport road, Gandhi nagar, Indore.

cellulitis and loss of vision. Spread along cribriform plate can result in intracranial involvement. Hematogenous spread to cavernous sinus and fatal cavernous sinus thrombosis has been widely reported. It can also spread by perineural invasion.

The oral signs of mucormycosis is painful, black, necrotic ulceration of the palate, becoming large and deep subsequently and cause denudation of underlying bone. The ulcers are also being reported on gingiva, lip and alveolar ridge³.

The differential diagnosis of a lesion presenting as palatal perforation should include tertiary syphilis, leprosy, squamous cell carcinoma of maxillary sinus, malignant salivary gland tumor arising from minor salivary glands of palate, extranodal NK T-cell lymphoma, Wegener's granulomatosis, aspergillosis and midline nonhealing granuloma^{2,3}.

Plain radiographs of sinuses and orbits may demonstrate sinus mucosal thickening, with or without air fluid levels, but this is not specific. CT scan with contrast and MRI may demonstrate erosions or destruction of bone or sinuses and help delineate the extent of disease. A definitive diagnosis of mucormycosis can be made by tissue biopsy or by positive culture or both. Initial culture of diseased tissue may be negative and histopathologic examination is essential for early diagnosis.^{3,8}

The cytologic specimen shows the presence of wide, ribbon like aseptate, hyaline hyphal elements often in the setting of extensive necrotic debris. Demonstration of aseptate hyphae with wide angle branching (45-90°) with angioinvasion is characteristic of mucor species.

As the disease progress with alarming rapidity, prompt and aggressive therapy is

essential. Treatment of zygomycosis requires several simultaneous approaches:

1. Surgical debridement: it is commonly defined as process of removing necrotic, devitalized tissue and foreign material from a wound. Wound with large quantities of necrotic debris are good candidates for surgical debridement.
2. Antifungal therapy: Amphotericin-B is the antifungal agent of choice. It is a polyene antifungal agent that acts by binding to sterols (primarily ergosterols) in the fungal cell membrane with a resultant change in membrane permeability. Amphotericin B causes nephrotoxicity, hence serum creatinine, potassium, magnesium and blood urea nitrogen have to be monitored periodically.
3. Studies have shown that hyperbaric oxygen exerts a fungistatic effect, the most important effect is to aid neovascularization, with subsequent healing in poorly perfused acidotic and hypoxic, but viable areas of tissue.
4. Medical management: correction of underlying condition that predisposes the patient to disease that is correction of underlying diabetic ketoacidosis, improving neutropenia either with granulocyte infusions or by enhancing endogenous neutrophil production with growth factors and discontinuation of iron chelation therapy or corticosteroids is often warranted^{3,1}.

Prognosis depends upon several factors such as infection site, rapidity of diagnosis, type and severity of immunosuppression. The mortality rates were nearly 85% in earlier days, however after the introduction of combined therapy more than 80% of patients can be expected to survive. Hope for cure, however lies in early recognition and aggressive treatment^{3,10}.

References:

1. Goel S, Palaskar S, Shetty VP, Bhushan Rhinomaxillary mucormycosis with cerebral extension. *J Oral Maxillofacial Pathology* 2009; 13: 14-7.
2. Auluck A. Maxillary necrosis by mucormycosis. A case report and literature review. *Med Oral Pathol Oral Cir Bucal* 2007; 12:E360-4.
3. Jaychandran S, Krithika C, Mucormycosis presenting as palatal perforation. *Indian J Dent Res* 2006; 17: 139.
4. Bakathir AA. Mucormycosis of jaw after dental extractions: two case reports. *Sultan Qaboos University Medical Journal*. 2006 December; 6(2): 77-82.
5. Chua JLL, Cullen JF. Fungal pansinusitis with severe visual loss in uncontrolled diabetes. *Ann Acad Med Singapore*. 2008; 37: 964-7.
6. Bhansali A, Bhadada S, Sharma A, Suresh V. Presentation and outcome of rhino-orbito- cerebral mucormycosis in patients with diabetes. *Postgrad Med J*. 2004; 80: 670-4.
7. Pagano L, Ricci P, Tonso A, Nosari AN. Mucormycosis in patients with hematological malignancies: A retrospective clinical study of 37 cases. *Br J Haematol* 1997; 99: 33-7.
8. Vazquez JA: zygomycosis, *e.Medicine*, 2002.
9. Ribes JA, Vanover CL, Baker DJ. Zygomycetes in human disease. *Clinical Microbiological Reviews*. 2000; 13: 236-301.
10. Pafrey NA. improved diagnosis and prognosis of mucormycosis. *Medicine*. 1986; 65: 113-23.

Corresponding Author:

Dr. NoopurShrivastava, P.G. Student,
Dept of Oral Medicine and Radiology,
Modern Dental College and Research
Center, Gandhi Nagar, Indore.
Email ID: dr.noopur6@yahoo.in
Phone number: 09893977673